

Human cingulate cortex and autonomic control: converging neuroimaging and clinical evidence

Hugo D. Critchley,^{1,2,4} Christopher J. Mathias,^{2,5} Oliver Josephs,¹ John O'Doherty,¹ Sergio Zanini,⁶ Bonnie-Kate Dewar,³ Lisa Cipolotti,³ Tim Shallice^{4,6} and Raymond J. Dolan¹

¹Wellcome Department of Imaging Neuroscience, Institute of Neurology, ²Autonomic Unit and ³Department of Neuropsychology, National Hospital for Neurology and Neurosurgery and Institute of Neurology, ⁴Institute of Cognitive Neuroscience, University College London, ⁵Neurovascular Medicine Unit, St Mary's Hospital, Imperial College, London, UK and ⁶Cognitive Neuroscience Sector, SISSA, International School for Advanced Studies, Trieste, Italy.

Correspondence to: Hugo D. Critchley, Wellcome Department of Imaging Neuroscience, Institute of Neurology, University College London, 12 Queen Square, London WC1N 3BG, UK
E-mail: h.critchley@fil.ion.ucl.ac.uk

Summary

Human anterior cingulate function has been explained primarily within a cognitive framework. We used functional MRI experiments with simultaneous electrocardiography to examine regional brain activity associated with autonomic cardiovascular control during performance of cognitive and motor tasks. Using indices of heart rate variability, and high- and low-frequency power in the cardiac rhythm, we observed activity in the dorsal anterior cingulate cortex (ACC) related to sympathetic modulation of heart rate that was dissociable from cognitive and motor-related activity. The findings predict that during effortful cognitive and

motor behaviour the dorsal ACC supports the generation of associated autonomic states of cardiovascular arousal. We subsequently tested this prediction by studying three patients with focal damage involving the ACC while they performed effortful cognitive and motor tests. Each showed abnormalities in autonomic cardiovascular responses with blunted autonomic arousal to mental stress when compared with 147 normal subjects tested in identical fashion. Thus, converging neuroimaging and clinical findings suggest that ACC function mediates context-driven modulation of bodily arousal states.

Keywords: autonomic; cingulate cortex; cognition, heart rate; sympathetic

Abbreviations: ACC = anterior cingulate cortex; fMRI = functional MRI; HF = high frequency; HRV = heart rate variability; LF = low frequency

Introduction

The anterior cingulate cortex (ACC) occupies a large fraction of the medial surface of the human brain and comprises cytoarchitecturally distinct subregions (Vogt *et al.*, 1992; Devinsky *et al.*, 1995). Damage to the ACC in humans is associated with reduction in spontaneous, compulsive and emotional motor responses. For example, transient akinesia and mutism has been observed following large bilateral ACC lesions that also involve adjacent regions such as the supplementary motor area (Nielsen and Jacobs, 1951; Barris and Schuman, 1953). Anterior cerebral artery haemorrhage, damaging the ACC together with the fornices, impairs attention and memory function (Laplane *et al.*, 1981). Personality changes, characterized by apathy, aboulia and anxiety reduction, have also been reported following large

ACC lesions (Nielsen and Jacobs, 1951; Barris and Schuman, 1953; Tow and Whitty, 1953; Folz and White, 1962; Laplane *et al.*, 1981). Circumscribed surgical lesions of the ACC, for treatment of psychiatric conditions, are reported to relieve obsessiveness and intractable pain and are associated with reduced self-generated and spontaneous motor responses (Cohen *et al.*, 1999).

There is, however, a paucity of reports detailing specific cognitive deficits following focal ACC damage in humans. Impaired ability to override dominant responses and to sequence novel cognitive operations is described in one post-cingulotomy patient (Ochsner *et al.*, 2001). Impaired response selection and error monitoring are reported in one patient with a focal right cingulate lesion (Turken and Swick,

1999; Swick and Turken, 2002). Evidence from rat lesion models also suggests motivational impairment (Bussey *et al.*, 1997; Walton *et al.*, 2002), yet in non-human primates evidence of marked effects of ACC lesions on 'cognitive' processes is limited, perhaps restricted to errors in response selection (Buchanan and Powell, 1982; Meunier *et al.*, 1997; Hadland *et al.*, 2003).

Recent accounts of ACC function frequently overlook earlier evidence highlighting its role in autonomic control. Electrical stimulation within both ventral and dorsal regions of the ACC in animals can elicit autonomic responses (including effects on heart rate and blood pressure (Ward, 1948; Kaada *et al.*, 1949; Kaada, 1951; Burns and Wyss, 1985; Chefer *et al.*, 1997). Similar autonomic responses to ACC stimulation are reported in humans (Pool and Ransohoff, 1949), while reduced visceral and autonomic reactions to opiate drug withdrawal represent an early observation of the effects of cingulotomy in pain management (Foltz and White, 1962).

Neuroimaging evidence, and to a lesser extent evidence from electroencephalography, implicate the ACC in cognitive processes involving attentional demand and executive control. The relationship between ACC activation and task difficulty or effort was highlighted in a review of more than 100 functional imaging (PET) studies (Paus *et al.*, 1998). ACC activity has also been related to error detection, monitoring, response inhibition, set-shifting, attentional selection and strategy formation (Carter *et al.*, 1999; Bush *et al.*, 2000; Gehring and Fencsick, 2001). An influential suggestion is that ACC function reflects evaluation of response rather than the processing of cognitive conflicts or strategy formation (Carter *et al.*, 2000; Gehring and Fencsick, 2001; van Veen *et al.*, 2001; Swick and Turken 2002). Nevertheless, activity in dorsal and genu regions of the ACC is also strongly associated with affective and bioregulatory processes, including nociception (Buchel *et al.*, 2002; Rainville, 2002), respiration (Liotti *et al.*, 2001) and the representation of somatosensory (Buchel *et al.*, 2002), viscerosensory (Aziz *et al.*, 2000; Athwal *et al.*, 2001) and autonomic arousal states (Fredrikson *et al.*, 1998; Critchley *et al.*, 2000a, b, 2001a, b, c). It is noteworthy that cognitive effort in tests that typically involve response conflict, such as the Stroop task, directly evokes autonomic changes in cardiovascular arousal (e.g. Hoshikawa and Yamamoto, 1997).

The control of cardiovascular function is critical to adaptive behaviour, with beat-to-beat variability in heart rate [heart rate variability (HRV), apparent in changes in intervals between R-waves on ECG] reflecting dynamic interactions between excitatory and inhibitory autonomic control mechanisms. Fluctuations in the RR interval are characterized by oscillatory patterns that include low-frequency (LF) (0.05–0.15 Hz) and high-frequency (HF) (0.15–0.50 Hz, respiratory rate) components. LF influence on HRV is largely, though not entirely, attributable to sympathetic nervous activity (Pagani *et al.*, 1986; Eckberg, 1997;

Montano *et al.*, 2001). HF influence on HRV is attributable to parasympathetic, vagally mediated activity (Montano *et al.*, 2001).

ACC pyramidal neurons project directly (and indirectly) to subcortical brain regions associated with homeostasis and autonomic control, including the hypothalamus (Ongur *et al.*, 1998), periaqueductal grey (An *et al.*, 1998) and pontine grey matter (Vilensky and van Hoesen, 1981; Porrino and Goldman-Rakic, 1982). These anatomical connections may support higher cortical influences on the regulation of bodily states. Projections from the ACC to brainstem sites arise throughout the ventral and dorsal extent. The genu cingulate, which receives inputs from 'motivational' regions, including the orbitofrontal cortex and amygdala, projects most strongly to the hypothalamus (Ongur *et al.*, 1998).

We previously investigated the central control of cardiovascular function using PET in healthy controls and patients with peripheral autonomic dysfunction (Critchley *et al.*, 2000a, b). In these studies, regions including the ACC, insula and pons were implicated in mediating changes in cardiovascular arousal during effortful cognitive and motor task performance. Autonomic control of the skin, indexed by electrodermal activity, is mediated by cholinergic sympathetic neurons and is closely related to thermoregulatory control. In some situations, including cold stimulation, response anticipation and emotional processing, electrodermal activity may be dissociated from neurally mediated cardiac responses. The ventromedial prefrontal, insula and parietal cortices are associated with electrodermal variation during motivational decision-making (Critchley *et al.*, 2000b). Furthermore, the ACC is implicated in electrodermal responses to emotive stimuli (Fredrikson *et al.*, 1998), during outcome anticipation (Critchley *et al.*, 2001a) and in mediating intentional modulation of electrodermal activity during biofeedback (Critchley *et al.*, 2001c). These latter observations highlight a role for the ACC in integrative control of sympathetic electrodermal activity responses, particularly the contextual generation of arousal states necessary to meet behavioural demands.

In the present study, we used event-related functional MRI (fMRI) and electrocardiography of healthy subjects to determine which brain areas are associated with the control of HRV during effortful cognitive and motor behaviours (Fig. 1). Each subject's ECG was continuously recorded during scanning. From the ECG, we derived regressors for LF and HF components of HRV to examine differential neural contributions from sympathetic and parasympathetic control processes. Functional imaging data were interpreted analytically with respect to both cognitive and motor task events and the ECG-derived regressors (HRV, and LF and HF power). By modelling cardiovascular responses within the analytical design, activity related to this common autonomic component could be examined independently of the modelled cognitive and motor contexts. On the basis of our previous human neuroimaging studies (Critchley *et al.*, 2000a, b; Critchley *et al.*, 2001b, c), we tested the hypothesis that

autonomic control would optimally account for variation in neural activity within regions including the dorsal ACC and insula cortices.

Because our neuroimaging data implicated the dorsal ACC in the control of sympathetic output, we subsequently studied three patients with lesions involving this cortical region. These patients were tested on autonomic function tests including ‘mental stress testing’, involving the pressured performance of mental arithmetic (serial subtractions of 7) (Mathias and Bannister, 1999) and underwent formal neuropsychological investigation. The specific hypothesis was that a lesion in this region would result in abnormalities in cardiovascular responses elicited by cognitive and motor effort. Consistent with a dissociation of autonomic and non-autonomic components of cognitive work, a secondary hypothesis was that the patients with ACC lesions would exhibit no neuropsychological deficits in attention or general cognitive performance (including mathematical ability), but would show impaired autonomic cardiovascular arousal during cognitive effort.

Methods

Functional imaging

Six healthy right-handed subjects (two women and four men, mean age 33 ± 2 years) underwent brain fMRI at 2 tesla [Siemens (Erlangen, Germany) Vision system, trajectory-based echoplanar sequence, echo time (TE) = 40 ms, repetition time (TR) = 3.9 s, 52 slices for whole-brain coverage] in a project approved by the Joint Ethics Committee of the National Hospital for Neurology and Neurosurgery and the Institute of Neurology and for which all subjects and patients gave written consent. During scanning, subjects performed alternating 2 min blocks of paced cognitive ‘*n*-back’ and isometric handgrip exercise conditions in counterbalanced repetitions. In the *n*-back conditions, individual consonant letters were presented visually for 1 s at 1 s intervals. Before each *n*-back block, the subject was informed whether the task was a 1-back task or a 2-back task. In the 1-back condition, the subject was required to signal by a brief squeeze of the pressure transducer each time a letter was sequentially repeated. In the more cognitively demanding 2-back task, the subject was required to signal each time a letter was repeated after an intervening letter (Fig. 1). Two handgrip exercise conditions required the subject either to repeatedly squeeze a pressure transducer at maximal pressure for 11 s and rest for 11 s (prompted by the words ‘SQUEEZE’ and ‘REST’ projected onto a screen viewed by the subject) or perform a similar task of a 6 s exercise followed by 6 s rest.

Subjects were familiarized with the task conditions prior to scanning. ECG was continuously recorded during scanning and the ECG signal trace was subsequently processed to remove radio frequency artefact, allowing calculation of the inter-beat interval and HRV from R-waves. Frequency components of HRV were derived using a fourth-order

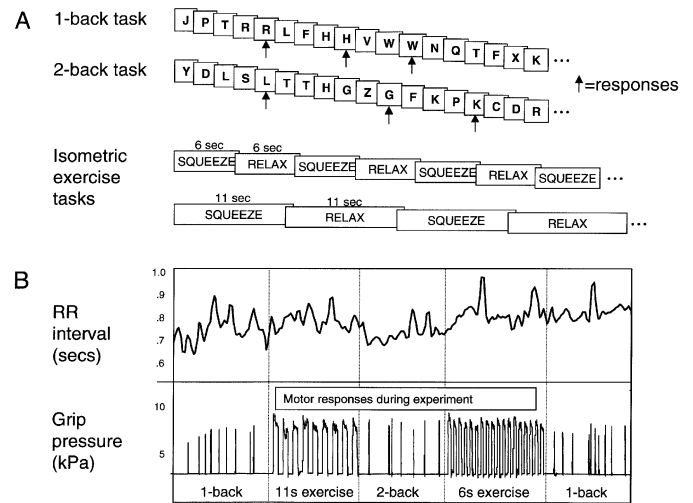


Fig. 1 Experimental design. Subjects were scanned continuously while performing repetitions of two cognitive tasks and two motor tasks. (A) The cognitive tasks employed the *n*-back design: the subject viewed sequential 1 s presentations of consonant letters (with 1 s interstimulus intervals). At the start of each *n*-back task block, the subject was visually prompted if the task was a 1-back or 2-back task. In the 1-back task, the subjects made a brief handgrip response if a letter was immediately repeated. In the 2-back task, the subject responded if the letter was repeated after a single intervening stimulus. In the two effortful motor tasks, the subject maintained a maximal handgrip squeeze for the duration of visual presentation of the word SQUEEZE and relaxed for intervening epochs indicated by presentation of the word REST. The two exercise conditions differed in the timing of these epochs, which were either 6 or 11 s in duration. This is illustrated diagrammatically. (B) Example subject data. Electrocardiography was continuously recorded during scanning, allowing derivation of regressors for heart rate variability (HRV) and low- and high-frequency power components of HRV. The figure illustrates changes in RR interval sampled for each volume acquisition above the handgrip response data for one subject during scanning. Task blocks were ~2 min in duration.

bandpass Butterworth filter with zero-phase forward and digital filtering at LF (0.05–0.15 Hz) and HF bands (0.15–0.50 Hz) associated with sympathetic and parasympathetic neural influence on heart rate. Both these frequency regressors were orthogonalized with respect to a control frequency band (0.7–1 Hz) to remove further artefact contamination. All ECG-derived regressors were subsequently resampled at the acquisition rate of each scan volume (3.9 s). In general, when we report sympathetic-related activity, we refer to analyses where the LF regressor was orthogonalized with respect to the HF regressor to remove shared variance within these respective indices of sympathetic and parasympathetic modulatory components. However, in order to ensure that our interpretation of sympathetic-related activity was robust, we also performed the converse orthogonalization (HF with respect to LF) for an otherwise identical analysis. Before orthogonalization with respect to each other, sympathetic and parasympathetic regressors were correlated (Pearson *r* across subjects, 0.46);

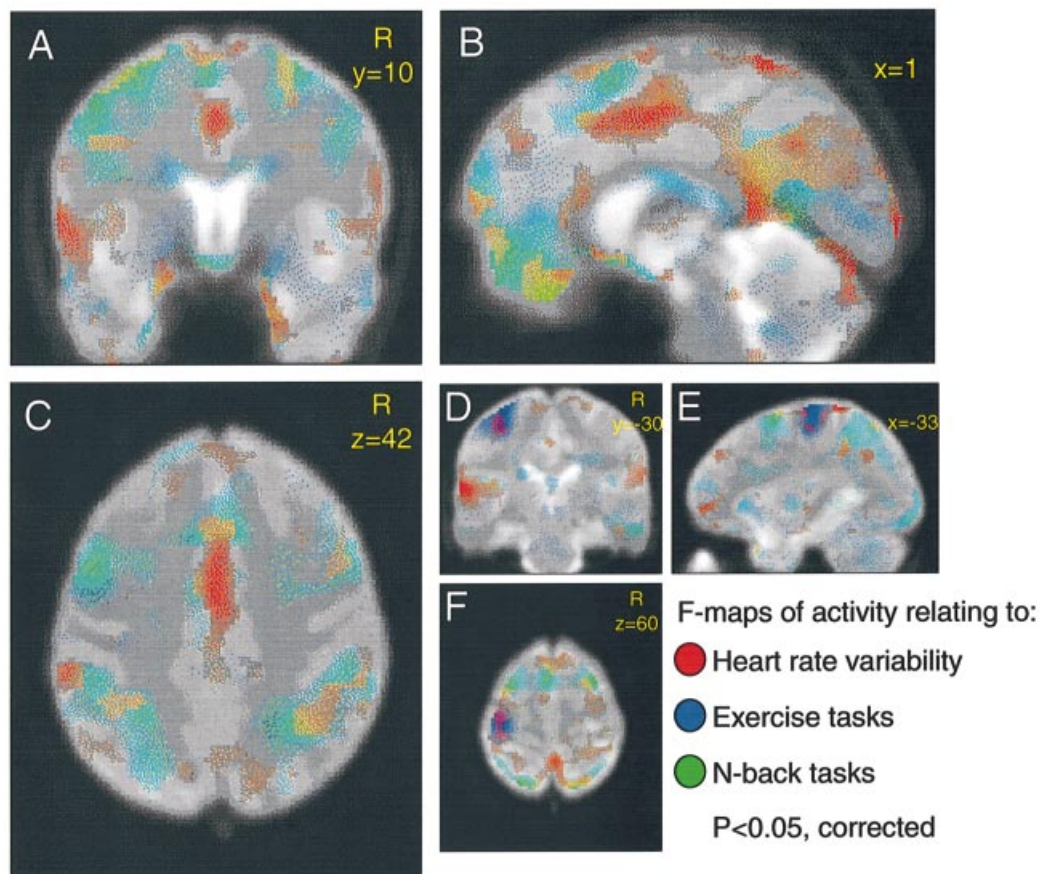


Fig. 2 Activity related to task performance and heart rate variability. Significant distinct changes in regional brain activity associated with cognitive and motor task performance and with heart rate variability (HRV), plotted for group data on sections of a normalized average fMRI (echoplanar) scan from all subjects. Activity changes (F test of significance) related to cognitive task performance are shown in green (each stimulus event of the two cognitive tasks, 1-back and 2-back, was modelled with a haemodynamic response function). Activity related to isometric exercise is shown in blue (6 and 11 s periods of the handgrip exercise were modelled as epochs convolved with a haemodynamic response function). Activity changes related directly to heart rate variability (HRV) are shown in red (F test of activity attributable to changes in HRV; the variance in RR interval over the experimental period was modelled as a continuous covariate). **A**, **B** and **C** represent coronal, sagittal and axial sections, respectively, to highlight anterior cingulate activity. Sections **D**, **E** and **F** highlight left somatomotor cortical activity related to exercise tasks. Coordinates in normalized space and laterality of coronal and axial images are shown in yellow. Data are presented at $P < 0.05$, corrected.

following orthogonalization they were uncorrelated ($r = -0.076$ in both analyses). Continuous regressors for HRV were modelled separately for the n -back (cognitive) and exercise tasks. Regressors for LF and HF spectral power modelled the whole scanning period.

Data analysis was conducted using Statistical Parametric Mapping (SPM99; <http://www.fil.ion.ucl.ac.uk/spm/spm99.html>) on a MATLAB platform (Mathworks Inc, Natick, MA, USA). Functional imaging data for each subject were realigned (motion-corrected), spatially transformed to standard stereotaxic space and smoothed (Gaussian kernel full-width-half-maximum 10 mm) prior to analysis. A statistical analytical design, employing the general linear

model, was constructed in which the 6 and 11 s periods of exercise were modelled as epochs of corresponding length, and presentations of letters in the n -back task were modelled as events (delta functions). Regressors modelling these epochs and events were convolved with a canonical haemodynamic basis function to model corresponding changes in blood oxygenation level-dependent (BOLD) contrast signal. Separate analytical designs were constructed that modelled the task conditions and ECG-derived regressors of interest with their temporal derivatives. In the first design matrix, HRV was the regressor of interest. In the second design matrix, sympathetic (LF) power and parasympathetic (HF) power were modelled as regressors of interest, with the

Table 1A Regional activity relating to HRV

Location	Side	Peak coordinates	F score
Inferior parietal lobule	R	-50, -42, 54	9.82
Somatosensory cortex	L	-24, -44, 70	8.29
Superior temporal gyrus		-62, -24, 10	8.30
Dorsal anterior cingulate	-	0, -4, 44	6.67
Genual anterior cingulate	R	12, 38, 14	4.79
Genual anterior cingulate	R	12, 40, 2	4.65
Medial temporal pole	R	28, 20, -30	7.89
Medial temporal pole/amygdala	R	18, -4, -28	5.90
Anterior insula	L	-58, 8, 0	7.92
Anterior insula	R	54, 14, -4	5.79
Medial orbitofrontal cortex	-	-4, 38, -22	5.61
Hypothalamus	-	6, 10, -19	4.65
Precuneus/medial parietal lobe	-	0, -58, 34	5.57
Posterior cingulate cortex	-	2, -44, 8	6.78

LF regressor orthogonalized with respect to the HF regressor. A third design matrix modelled the converse orthogonalized HF and LF regressors.

We tested for significant effects first, using bidirectional F-contrasts to identify changes in regional brain activity attributable to task performance and associated with HRV. We then used T-contrasts to identify activity associated with increases in sympathetic and parasympathetic spectral power. Data were analysed initially in fixed-effects group designs. Conjunction analyses were subsequently used to test for significant changes in regional brain activity common across individual subjects (Friston *et al.*, 1999). For completeness, a stringent second-level random effects analysis of the statistical contrast images for sympathetic (LF) power for each subject was performed to determine the robustness of the observed autonomic-related effects. Data are reported at whole brain corrected significance (Genovese *et al.*, 2002).

Patient testing

Three patients with neuroradiological evidence of localized brain lesion (Patient 1 on CT, Patients 2 and 3 on MRI) involving the ACC were clinically assessed to determine the integrity of autonomic nervous control of the cardiovascular system. Patient 1, tested approximately 3 years after a traumatic intracranial bleed, was a 47-year-old woman with a medial prefrontal lesion involving bilateral ACC. On the right, the lesion extended inferiorly to involve the orbitofrontal cortex. Dorsally, the lesion involved the superior frontal gyrus. On the left, the lesion extended to the genu of the corpus callosum. Patient 2 was a 39-year-old male assessed 2 years after partial resection of a bilateral (predominantly left-sided) medial frontal oligodendroglioma arising from the ACC. The tumour extended throughout the dorsal extent of the ACC posterior to the surgical lesion. There was evidence of tumour also infiltrating the adjacent dorsolateral and ventral prefrontal cortices, the medial

Table 1B Regional activity changes in high- and low-frequency bands in RR interval

Location	Side	Peak coordinates	t score
Increased low-frequency power (sympathetic)			
Insula	L	-58, 8, -2	5.62
Insula	R	44, 18, -10	4.38
Anterior cingulate	R	4, 18, 34	4.55
Anterior cingulate	-	4, 6, 42	4.39
Anterior cingulate	-	2, -4, 46	3.88
Medial temporal pole	R	22, 10, -20	4.02
Somatosensory cortex	R	66, -12, 28	6.25
Inferior parietal lobule	R	60, -30, 30	5.14
Superior temporal gyrus	L	-66, -26, 8	5.14
Mediodorsal thalamus	L	-6, -16, 16	4.03
Increased high-frequency power (parasympathetic)			
Paracentral/superior parietal lobule	L	-28, -40, 72	5.71
Superior parietal lobule	R	26, -58, 66	4.55
Fusiform gyrus	L	-22, -54, -14	4.84
Cerebellar cortex	R	44, -52, -34	4.83
Somatomotor cortex	L	-22, -8, 58	4.82
Somatosensory cortex	R	62, -20, 46	4.44
Mediodorsal prefrontal cortex/SMA	R	-6, 6, 68	4.27
Cingulate	L	-14, -8, 40	3.86

SMA = supplementary motor area

temporal lobe and the insula. Operatively, tissue was removed from the left superior frontal gyrus, dorsal ACC, paracingulate and genual cingulate cortices. Patient 3 was a 28-year-old woman assessed after removal of a predominantly right prefrontal glioma. The tumour involved much of the ACC, extending anteriorly towards the frontal pole, posteriorly to the midcingulate and inferiorly to involve the genual region. There was also some involvement of the corpus callosum, superior frontal gyrus and frontal white matter (Fig. 4). Formal neuropsychological investigation of these three patients employed a comprehensive neuropsychological test battery tapping a wide variety of cognitive functions. We found that all patients had well-preserved general intellectual functions. No focal cognitive deficits were observed. All patients had preserved mental arithmetic, speed and attention abilities. Moreover, they performed generally well on a large number of demanding clinical tasks sensitive to frontal executive functions. The only exception was the slightly weak performance of Patients 1 and 2 on a couple of selected frontal tests. Details of these tests are given in Table 2. A more comprehensive account of the neuropsychological profiles of these patients will be the subject of a future report.

The autonomic function tests were derived from a clinical test battery used to screen neurological patients for suspected autonomic failure (Mathias and Banister, 1999). Cardiovascular responses to respiratory, postural, cold, mental effort and exercise challenges were conducted with simultaneous monitoring of beat-to-beat changes in heart rate and blood pressure (Portapres2; TNO Biomedical

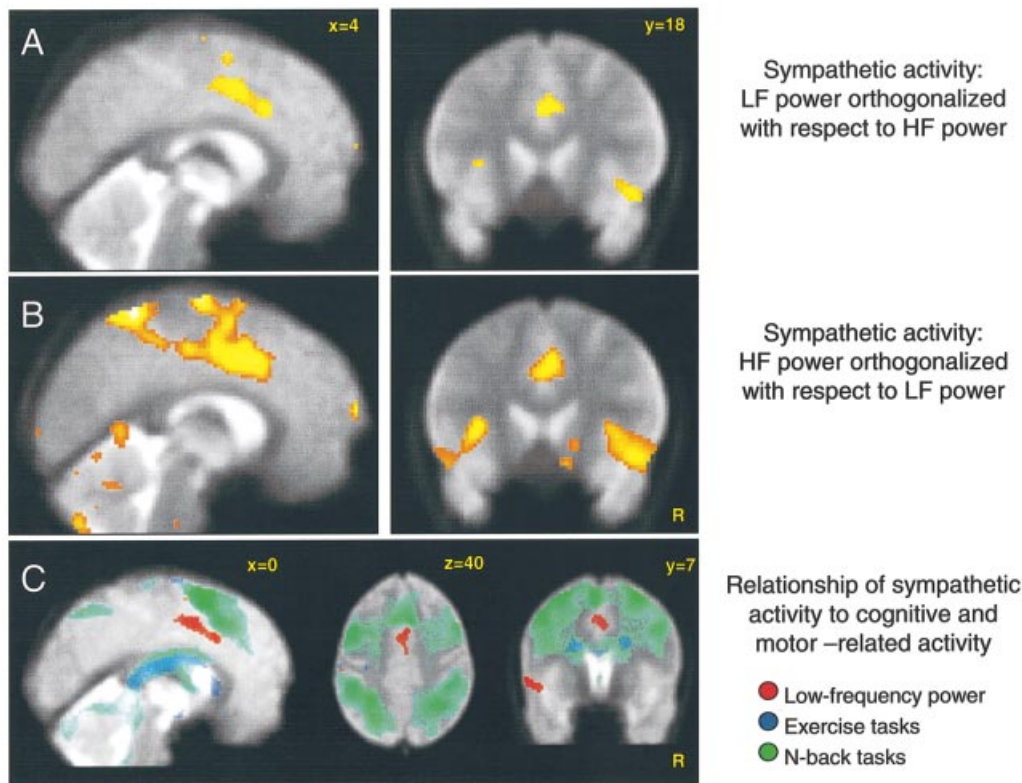


Fig. 3 Brain activity associated with sympathetic cardiac control. (A) Significant changes in regional brain activity associated with increasing low-frequency (LF, sympathetic) power across derived from frequency analysis of interbeat interval (from ECG). Group data (t test of activity relating to increased LF power, $P < 0.05$, FDR corrected) are plotted on sagittal and coronal sections on the average normalized fMRI images from all subjects. Numbers illustrate laterality (mm) in normal space. This t contrast represents activity that is uniquely related to sympathetic influences on heart rate and is distinct from activity related directly to cognitive or motor task performance, or to HF components of heart rate, to which the LF regressor was orthogonalized. (B) Significant regional activity related to LF sympathetic power in a second analysis, where HF was orthogonalized with respect to the LF regressor. In this orthogonalization, shared variance in activity between heart rate and LF regressors is retained by the LF component. The striking correspondence of this analysis with that illustrated in panel A underlines the sympathetic basis of the observed cingulate and insular activity. (C) Anatomical segregation of activity relating to effortful cognitive and motor task performance from activity related to increasing LF power (LF orthogonalized with respect to HF regressor, as in A). Activity within distinct regions of the dorsal cingulate and insula relate to sympathetic arousal rather than cognitive task performance. The t maps of data are plotted on coronal, sagittal and axial sections of an average normalized functional image. Coordinates in normalized space and laterality of coronal and axial images are shown in yellow. Activity is thresholded at $P < 0.05$, false discovery rate (FDR) corrected.

Instrumentation, Amsterdam, The Netherlands). The cognitive effort challenge in this clinical setting involved the overt performance of serial subtractions of the number 7 from 400 in front of the examiner, who corrected and encouraged the subject to perform the test as rapidly as possible. The effortful motor challenge (isometric exercise) required the subject to hold a grip of a pneumatic cuff for 3 min at 30% of their maximal grip strength. Performance of the standardized clinical autonomic tests of autonomic integrity allowed us to clinically compare the heart rate and blood pressure responses of the individual patients with ACC lesions with normative data from 147 healthy subjects who were tested using an identical protocol by the same evaluating autonomic units (Mathias and Bannister, 1999). These clinical tests of

cardiovascular autonomic responses therefore differed from the n -back and paced isometric exercise tasks used in the neuroimaging study, in which the analytical requirement was for carefully controlled timing of stimuli and monitoring of performance within the unique fMRI environment. Furthermore, ECG was recorded simultaneously with the Portapres2 data when Patients 2 and 3 underwent autonomic function testing. Interbeat intervals from ECG enabled us to derive measures of HRV and of LF/HF power. Comparative ECG data were obtained from 12 control subjects (seven women, five men, mean age 29 ± 6 years, tested in identical circumstances and judged to have no impairment of autonomic function). The method used to obtain measures for frequency bands corresponding to sympathetic and

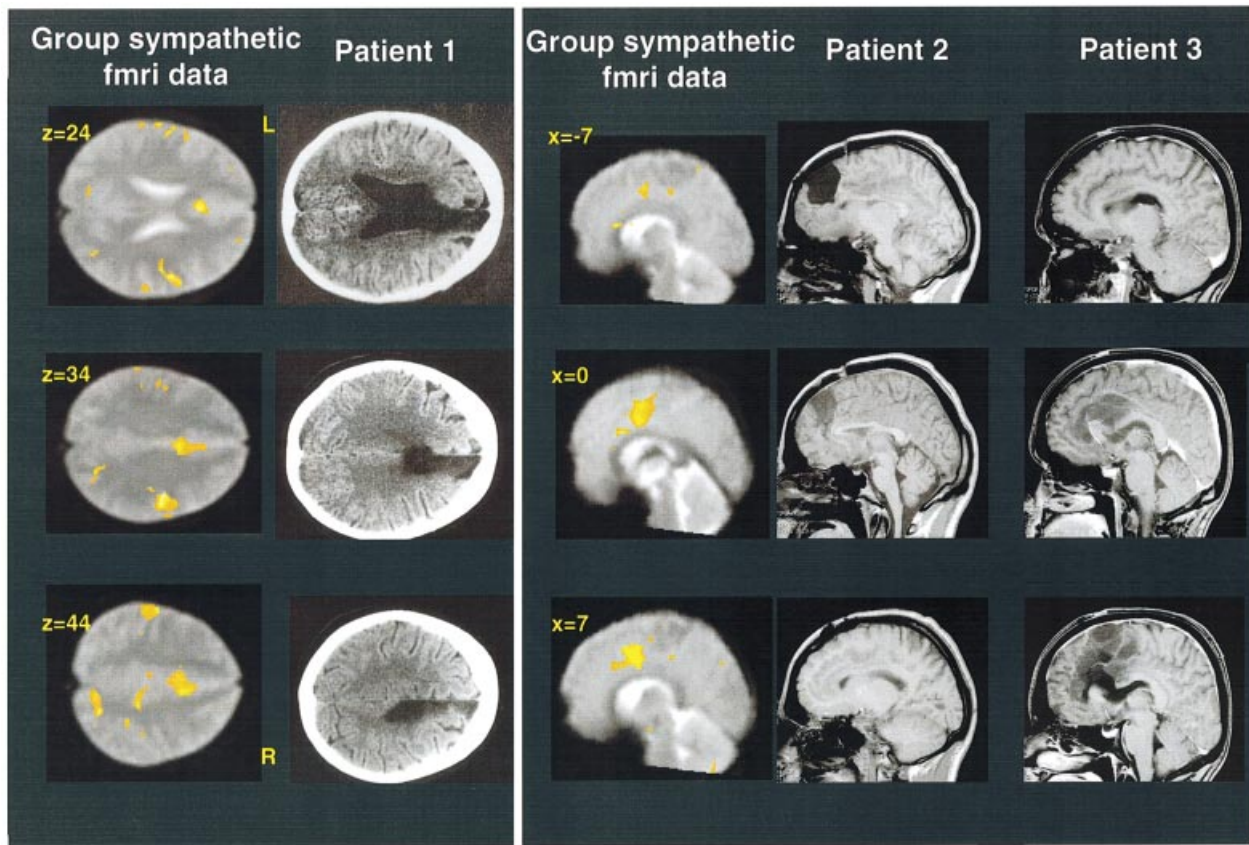


Fig. 4 Patients with lesions involving the anterior cingulate cortex. Location of damage relative to fMRI data. The figure illustrates sections from head scans of three patients with damage affecting the anterior cingulate cortex, together with equivalent sections of an average normalized functional image depicting the location of sympathetic-related cingulate activity derived from random effects analysis across six subjects (cluster-level significance $P < 0.05$, family-wise error, FWE corrected). The columns to the left show the fMRI data in coronal sections adjacent to slices of a CT scan from Patient 1, a 47-year-old woman who acquired an ACC lesion following a traumatic intracranial bleed. The three columns to the right show sagittal sections depicting sympathetic-related cingulate activity next to sagittal sections from structural MRI scans of Patient 2 (a 39-year-old male) and Patient 3 (a 28-year-old woman). Both had medial frontal gliomas (predominantly left-sided in Patient 2 and right-sided in Patient 3) and had undergone surgical debulking of tumour. In Patient 2, the tumour infiltrated tissue bilaterally throughout the genu and dorsal ACC, including the region identified in the functional imaging study behind the surgical excision. However, in contrast to Patient 3, this is less apparent from gross inspection of scans, due to a relative absence of cystic changes.

parasympathetic cardiac influences was the same as for the imaging experiment.

Results

In the functional imaging experiment, healthy subjects showed enhanced activity associated with performance of the cognitive tasks (bidirectional F -test of both 1- and 2-back tasks) in regions that included the dorsolateral, medial and orbitofrontal cortices and medial and lateral parietal cortices. Effortful motor task performance was associated with activity changes that were maximal in the contralateral sensorimotor cortex (at hand and forearm level) and in the striatum, cerebellum and pons. A distributed pattern of regional activity was observed in relation to HRV (bidirectional F test). HRV-related activity overlapped with cognitive and motor-related activity (consistent with the absence of implicit

orthogonalization of regressors in F -test analyses). Interestingly, the largest cluster was located bilaterally in the dorsal ACC. This region was associated with both cognitive and motor activity, and extended anteriorly towards a dorsal prefrontal area uniquely associated with cognitive task performance and posteriorly towards motor cingulate regions (Fig. 2). Significant clusters of HRV-related activity were also observed in the genu ACC, bilateral insula, orbitofrontal, retrosplenial, medial parietal, bilateral somatosensory and superior temporal cortices and hypothalamus (Fig. 2).

Conjunction analysis confirmed that, for the majority of regions, notably the dorsal ACC, medial orbitofrontal cortex, insula, hypothalamus and medial parietal lobe, HRV-related activity was independent of whether the subject was engaged in cognitive or motor task performance (Table 1A). Overlap was additionally observed between HRV-related and 'cogni-

Table 2A Clinical details of patients with ACC damage

	Patient 1	Patient 2	Patient 3
Age (years), gender, handedness	47, F, right	39, M, right	28, F, left
Years of full-time education	13	13	15
Cause of lesion	Trauma	Glioma	Glioma
Testing in relation to time of surgery	3 years	4 years	3, 7 and 13 weeks

Table 2B Neuropsychological test scores

	Patient 1	Patient 2	Patient 3
VIQ	100 (WAIS)	99 (WAIS-R)	113 (WAIS-R)
PIQ	117 (WAIS)	113 (WAIS-R)	112 (WAIS-R)
RMT words (percentile)	nt	49/50 (>75th)	50/50 (>75th)
RMT faces (percentile)	nt	50/50 (>95th)	49/50 (=95th)
PAL trial 1 (percentile)	nt	21/24 (50–75th)	23/24 (=90th)
PAL trial 2 (percentile)	nt	24/24 (>50th)	23/24 (>50th)
RCFT recall (percentile)	nt	30/36 (>96th)	26/36 (=73rd)
GNT (percentile)	nt	21/30 (=50th)	25/30 (=90th)
OD (5% cut-off)	18/20 (>5)	19/20 (>5)	19/20 (>5)
Dsymbol (ss)	8 (WAIS)	7 (WAIS-R)	14 (WAIS-R)
Trails A (s)	nt	37 (20–30th)	18 (80–90th)
Trails B (s)	nt	86 (25–50th)	44 (>90th)
MCST categories	6	6	6
MCST total perseverative errors (percentile)	0 (0)	1 (33rd)	0 (0)
Proverbs	5/5	6/8	8/8
Stroop C/W (percentile)	24 (wnl)*	94 (15–17th)	112 (100th)
Hayling (ss)	nt	3	7
Brixton (ss)	5	10	10
FAS total (percentile)	22 (8–14th)*	24 (4th)	49 (66th)
Animals (percentile)	20	11 (2nd)	25 (73rd)
BADS number switch (ss)	nt	4	4
BADS six elements (ss)	nt	3	4

F = female; M = male; WAIS-R = Wechsler Adult Intelligence Scale—Revised (Wechsler, 1981); (WAIS) = Wechsler Adult Intelligence Scale (Wechsler, 1955); RMT = Recognition Memory Test (Warrington, 1984); PAL = Paired Associate Learning Test (Warrington, 1996); RCFT = Rey Complex Figure Test (Osterreith, 1944); GNT = Graded Naming Test (McKenna and Warrington, 1980); OD = Object Decision (Warrington and James, 1991); Dsymbol = Digit Symbol (Wechsler, 1981); Trails A = Trail Making Test, Part A; Trails B = Trail Making Test, Part B (Reitan and Wolfson, 1985); MCST = Modified Card Sorting Test (Nelson, 1976); Stroop C/W = Stroop Colour/Word task (Trenerry *et al.*, 1989); Hayling = Hayling sentence completion test (Burgess and Shallice, 1997); Brixton = Brixton spatial anticipation test (Burgess and Shallice, 1997); FAS = controlled oral word association test (Spreen and Strauss, 1998); BADS = Behavioural Assessment of the Dysexecutive Syndrome (Wilson *et al.*, 1996); nt = not tested; wnl = within normal limits; * = Italian version of task; ss = scaled score.

tive' activity in the orbitofrontal, retrosplenial and lateral parietal cortices. HRV-related activity was also present in the somatomotor cortical region activated during motor tasks, consistent with a cortical motor contribution to central command.

In a second analysis, running indices of LF and HF power were entered with task-related regressors to test for activity reflecting changes in sympathetic and parasympathetic output. We used unidirectional *t* tests to test for activity relating uniquely to cognitive processing, motor activity and autonomic regulation. Shared variance was explicitly removed from LF and HF regressors before they were entered into this analysis. Group analyses revealed activity in bilateral dorsal ACC, insula, hypothalamus and inferior parietal and

somatosensory cortices associated with increasing LF (sympathetic) power (Table 1B). Importantly, the association between enhanced ACC and insular activity with increasing sympathetic power was independent of whether the LF regressor was orthogonalized with respect to the HF regressor or vice versa. Because of implicit orthogonalization within the multiple regression *t*-test analysis, this activity was also dissociable from activity relating to the events within the cognitive or exercise tasks (Fig. 3). We also used conjunction analyses across subjects to demonstrate that the same ACC and insular regions were associated with increased sympathetic (LF) modulation of heart rate in each subject. Furthermore, the robustness of this effect was demonstrated in a second-level random effects analysis of sympathetic-

Table 3 Autonomic function tests in three patients with anterior cingulate lesions

Autonomic function test	Patient 1		Patient 2		Patient 3	
	SBP	H R	SBP	HR	SBP	HR
Mental arithmetic	↓***	↓***	↓*****	↓**	↓***	↓**
Isometric exercise	↑*****	↑*****	↓*****	—	↓*****	↓*****
Standing						
2 min	↓****	↓***	↓*****	↑*****	↓*****	↑****
5 min	↓****	↓***	↓***	↑*****	↓****	↑*****
Cutaneous cold	↓**	—	↑*****	↑*****	↑*****	↑*****
Hyperventilation	—	↑*****	—	—	—	↓***

SBP = systolic blood pressure change; HR = heart rate change. ↑ = Significantly greater cardiovascular response compared with normative population; ↓ = significantly blunted cardiovascular response compared with normative population. **2–3 SDs; ***3–4 SDs; ****4–5 SDs; *****≥5 SDs from mean response in normative population.

related activity across the six subjects. In this analysis, bilateral ACC activity was associated with increasing sympathetic power in the genu anterior cingulate, extending posteriorly to midcingulate (x, y, z coordinates 2, 22, 24, $t = 3.58$, and 4, 4, 34, $t = 3.07$, $P < 0.01$, corrected at cluster level). Activity in bilateral anterior and posterior insulae also reached this level of significance (Fig. 4). Significant activity associated with increasing HF (parasympathetic) power was observed in the left somatosensory cortex and precuneus, and in the left dorsal cingulate, left anterior insula and cerebellar vermis (Table 1). Areas active in responses to increases in both sympathetic and parasympathetic power (conjunction of t tests) included the insula and ACC bilaterally.

These neuroimaging findings indicate cortical and subcortical contributions to autonomic cardiovascular control and, more specifically, to sympathetic influences on heart rate. Most strikingly, they dissociate dorsal ACC activity contributing to visceral regulatory processes from non-autonomic activity related to cognitive or motor task performance. Moreover, they suggest that regulation of autonomic arousal may account for previous reports of ACC activity during emotional and cognitively demanding tasks, as well as cingulate responses to respiratory, noxious or visceral stimulation (Aziz *et al.*, 2000; Athwal *et al.*, 2001; Liotti *et al.*, 2001; Buchel *et al.*, 2002; Rainville, 2002). This is in contrast with some current cognitive interpretations of dorsal ACC function (Carter *et al.*, 1999, 2000; Bush *et al.*, 2000).

A direct prediction from our neuroimaging findings is that damage to this ACC region should impair the generation of normal sympathetic cardiovascular arousal during effortful cognitive and motor behaviours, but may have limited impact on neuropsychological performance. We therefore examined the cardiovascular responses and the neuropsychological profiles of three patients with lesions involving this dorsal region of the ACC (Fig. 4). We used a clinical autonomic test battery designed to screen for abnormalities in cardiovascular autonomic control (Mathias and Bannister, 1999), and a neuropsychological test battery that included a wide variety of cognitive tasks. The autonomic battery included low-level

autonomic challenges (hyperventilation, cold, postural challenge) and behavioural test challenges that drive autonomic responses via predominantly central mechanisms [effortful cognitive (mental arithmetic) and motor (isometric exercise) tasks]. We hypothesized that dorsal ACC lesions would specifically impair autonomic responses to volitionally mediated behaviours, particularly during effortful cognitive processing, and to a lesser extent during motor effort. By contrast, ‘low-level’ autoregulatory and peripherally mediated reflex cardiovascular responses may be variably affected, depending on the extent of the lesion beyond this dorsal ACC region.

The clinical characteristics of each patient and their performance on a neuropsychological test battery are detailed in Table 2A and B. Noteworthy is the fact that, despite differences in the extent of their lesions, all three patients showed well-preserved cognitive functioning. All had scores in the average or high-average range in the arithmetic subtest of the Wechsler Adult Intelligence Scale—Revised and performed entirely satisfactorily on tests of speed and attention. Moreover, all three patients, on a series of rather demanding standardized clinical tests sensitive to frontal executive dysfunction, performed remarkably satisfactorily. The only minor exceptions were a weak performance of Patients 1 and 2 on selected frontal tests (phonemic fluency and Brixton for Patient 1 and Stroop and Hayling for Patient 2).

Consistent with the prediction that dorsal ACC lesions would disrupt autonomic responses integrated with cognitive and motor behaviours, the three patients had abnormalities in autonomic function when compared with normative data derived from 147 healthy individuals who had been tested previously on identical tasks by the same clinical units. Notably, all three patients showed blunted cardiovascular responses to effortful cognitive task performance (mental stress, overt rapid serial subtraction of 7). No qualitative difference was noted between the performances of the three ACC patients and control subjects undergoing autonomic function tests on any of their attempts in the mental stress task. All three patients performed satisfactorily in terms of

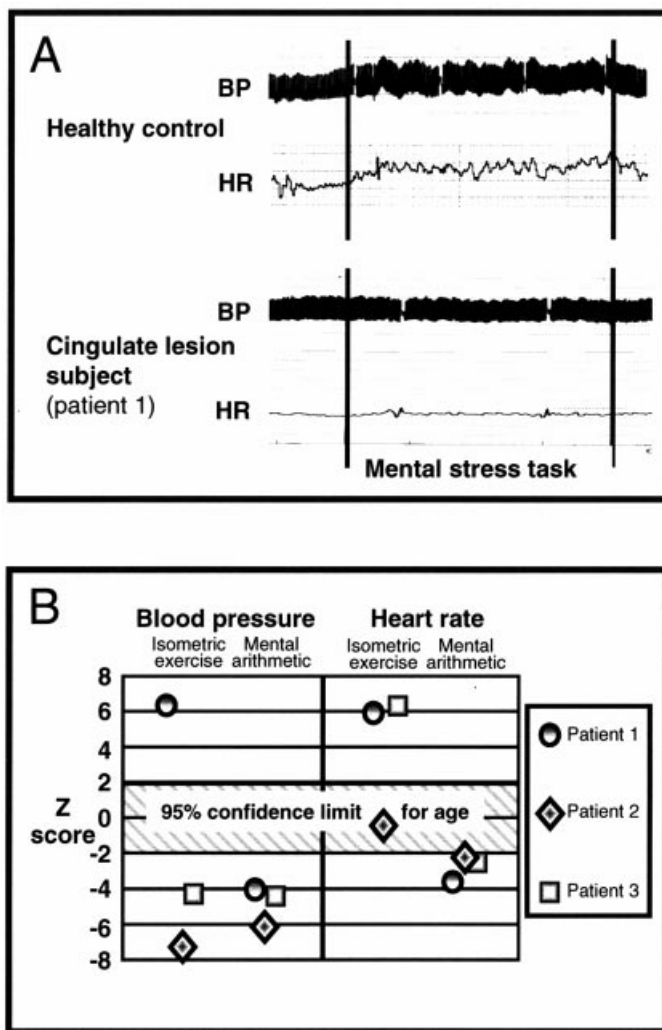


Fig. 5 Effects of ACC lesions on autonomic responses. (A) *Upper traces:* example of a healthy robust response to mental stress testing, overt serial subtractions of 7. *Lower traces:* similar flattened response in a patient with a cingulate lesion (Patient 1). The thick traces represent continuous (beat-to-beat) recording of blood pressure (BP) (upper/lower limits represent systolic/diastolic blood pressure), and the thin traces represent heart rate (HR) (beat-to-beat recording), both recorded simultaneously using Portapres2 apparatus from the finger-pulse waveform. The y axis divisions are equivalent to 10 mm Hg or 10 beats per min. Brief calibration artefacts appear on the graphs. (B) Results of clinical autonomic function tests in the three patients with ACC lesions, plotted as Z scores relative to normative data from 147 subjects tested at the autonomic units. These data indicate blunting of heart rate and blood pressure responses to mental stress in all three subjects and a mixed pattern of abnormal responses to isometric exercise (atypical elevation of blood pressure in Patient 1, blunting in Patients 2 and 3).

both accuracy and rate of serial subtraction, in keeping with their normal scores on neuropsychological evaluation of mathematical ability, speed and attention. In healthy individuals, the mental stress task elicits significant increases in systolic blood pressure (population mean \pm SD, 17 ± 4 mm

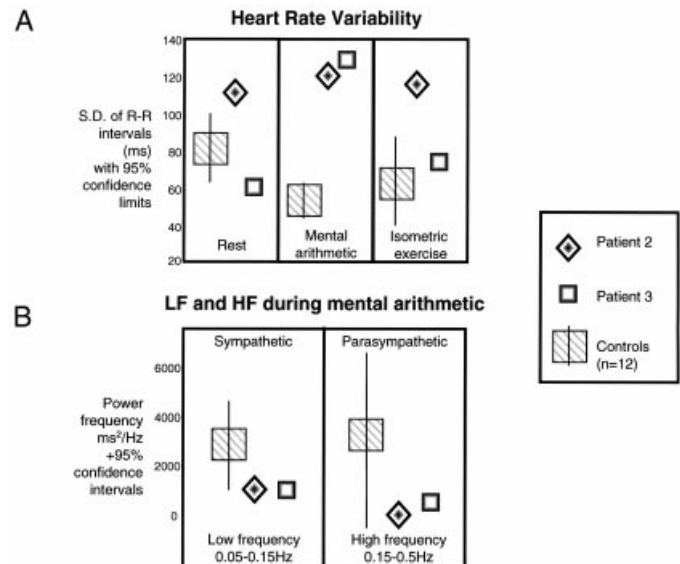


Fig. 6 Heart rate variability (HRV) in anterior cingulate patients. ECG-derived measures of HRV. ECG data were recorded from two patients with ACC lesions and 12 healthy controls during performance of autonomic screening tests including cognitive effort (mental arithmetic: 3 min overt serial subtractions of 7) and physical effort (isometric exercise: 3 min handgrip squeeze at 30% of maximum). (A) HRV is plotted as the standard deviation of RR interval during rest, mental arithmetic and isometric exercise for controls and patients. Both patients show abnormally high (above 95% confidence limit) HRV during cognitive effort (mental arithmetic), and for Patient 2 (a 39-year-old male) HRV was also abnormally high in rest and exercise conditions. (B) Power spectrums of RR interval variability were derived from the ECG to determine low- and high-frequency (LF and HF) influences on heart rate that index sympathetic and parasympathetic cardiac regulation. The figure plots the LF and HF power in controls and two cingulate-lesioned patients during mental stress testing. Relative to controls, both patients demonstrated low levels of LF and HF power, with LF power at the lower 95% confidence limit compared with controls during mental arithmetic. These data support the proposal that the ACC has a central role in cognitively driven modulation of autonomic influences on the heart.

Hg) and heart rate (7 ± 3 beats per min), which were not observed in these patients (Table 3, Fig. 5). In responses to isometric exercise challenge, the ACC-lesioned patients showed abnormalities in cardiovascular responses, but this was not consistent across subjects, perhaps reflecting variable up-regulation of peripheral autonomic reflexes from impaired 'central command' (generated in part by the motor cortex) during exercise (Turner, 1991). ACC-lesioned patients also had abnormalities in a number of 'low level' sympathetic responses, for example to orthostatic challenge (Table 3), suggesting that ACC activity is closely linked to homeostatic autonomic mechanisms. Again, extension of the lesions beyond the dorsal ACC may account for these less predictable perturbations of cardiovascular autoregulation. Nevertheless, our observations remain consistent with the hypothesis that dorsal ACC lesions disrupt autonomic cardiovascular control.

Further evidence for an association between ACC lesions and disruption of autonomic, particularly sympathetic, control of the heart was observed in analyses of ECG-derived measures of HRV and of LF and HF power during clinical testing. These data were available in two ACC patients (Patients 2 and 3). Both showed significantly greater variability in heart rate (RR interval) during mental arithmetic stress testing than controls ($n = 12$) (Fig. 6). Patient 2 also demonstrated significantly greater HRV during both rest and isometric exercise than control subjects. Power spectral analysis of HF and LF components of HRV revealed abnormalities in sympathetic and parasympathetic influences on heart rate in these patients with anterior cingulate lesions that were characterized by relative reductions in sympathetic power in both patients, notably during cognitive effort (Fig. 6). Together, these findings indicate disruption of sympathetic cardiovascular regulation by ACC lesions and support the hypothesis that ACC damage impairs the generation of cardiovascular arousal during cognitive effort. Moreover, the observation that ACC lesions may be associated with abnormalities in lower-level cardiovascular responses suggests this region to be closely linked to homeostatic centres.

Discussion

In the present study, our fMRI, neuropsychological and physiological observations provide evidence for a direct link between ACC activity and modulation of cardiac function via sympathetic output. These findings build on previous neuroimaging observations relating circumscribed cingulate activity to increases in blood pressure during effortful tasks in healthy individuals or in the absence of autonomic arousal during effort in patients with peripheral autonomic denervation (Critchley *et al.*, 2000a, 2001b). This same dorsal ACC region is also implicated in mediating interactions between cognitive processing and bodily sympathetic arousal indexed by electrodermal activity (Critchley *et al.*, 2001c). A parsimonious interpretation is that a principal function of the ACC is the regulation of bodily states of arousal to meet concurrent behavioural demands. ACC activity during cognitive, motor and emotional tasks (Carter *et al.*, 1999; Bush *et al.*, 2000; Phan *et al.*, 2002) and in response to visceral or painful stimuli (Aziz *et al.*, 2000; Rainville, 2002) reflects challenges that engender contextual modulation of bodily arousal via autonomic nervous activity. The observation that patients with ACC damage fail to generate contextually appropriate autonomic (notably sympathetic) outputs corroborates the anatomical neuroimaging data by providing evidence that this region is *necessary* for the appropriate generation of autonomic arousal during effortful cognitive and physical work.

The anterior cingulate patients were largely unimpaired on a wide variety of tests of cognitive functioning, including mental arithmetic, and tests of sustained attention and concentration. Interestingly, their performance was satisfac-

tory across a series of rather demanding standardized clinical tests sensitive to frontal executive dysfunction. These observations suggest that the ACC may fulfil a rather limited role in general attentional or executive control of cognitive functions.

The anatomical extent of the human ACC and the functional modularity of adjacent cortices have prompted attempts to parcellate this region into discrete functional regions (Vogt *et al.*, 1992; Carter 1999; Bush *et al.*, 2000). Much emphasis is placed on a distinction between 'cognitive' (dorsal) and 'emotional' (genual) regions of the ACC, based on differential activity during some cognitive and emotional tasks. The dorsal ACC has strong reciprocal connections with the dorsolateral prefrontal, neostriatal, premotor and lateral temporoparietal cortices, in contrast to the subgenual ACC, which connects with neighbouring ventral striatal, orbitofrontal and medial temporal regions. Consequently, subgenual ACC activity has been associated with many tasks embodying a strong emotional or motivational component (Bush *et al.*, 2000). Nevertheless, the dorsal ACC shows frequent activation during emotional processing, particularly in the context of concomitant cognitive demand (Phan *et al.*, 2002). In our fMRI study, activity related to HRV and sympathetic cardiac influence was observed both in dorsal and genual anterior cingulate regions. Activity in adjacent regions of the medial and orbital prefrontal cortex has previously been associated with increased HRV (reflecting decreased sympathetic activity) in a PET study of induced emotional states (Lane *et al.*, 2001). Although different tasks may engage subregions of the cingulate, our fMRI findings indicate that a common dorsal cingulate region is involved in autonomic control during cognitive processing and motor action. The data further indicate that autonomic-related activity within the anterior cingulate is dissociable from activity generated by specific cognitive task demands. Nevertheless, prefrontal cortical regions adjacent to autonomic-related cingulate activity were uniquely activated by cognitive task performance. Specialization of these dorso-medial and dorsolateral regions in response selection and monitoring (Rowe *et al.*, 2000) suggests that these regions provide afferent drive to the cingulate cortex for the generation of transient autonomic responses in these contexts. The functional role of autonomic transients in cognitive processing remains to be fully elucidated, yet its absence is likely to contribute to the observed apathy, aboulia and reduced spontaneity in some patients.

The primacy of autonomic control in ACC function is also demonstrated by the three patients, who all had lesions principally affecting the ACC. Each of these patients independently demonstrated abnormalities in the generation of cardiovascular arousal during cognitive effort. This was dissociable from their performance on a variety of cognitive tasks. In particular, performance in a series of executive function tasks involving response conflicts was largely preserved. It is noteworthy that two patients obtained an entirely normal score on the Stroop task, with only one patient

obtaining a marginally weak score on this task. The Stroop task is well known to require the detection and resolution of conflict between a dominant response (e.g. reading words) and a less habitual alternative (ink-colour naming). At the very least, largely preserved function on the Stroop, a paradigmatic task that engenders response conflict, suggests that the computational processes required to overcome response conflict in this task are dissociable from those involved in the higher-order generation of autonomic states. This finding is all the more robust since all three patients had large lesions that not only affected most of the supragenual cingulate cortex bilaterally, but also involved frontal white matter and some non-cingulate prefrontal cortical regions. Variations between patients in the anatomical extent of the cingulate lesion appear to account more for differences in expression of cardiovascular autonomic abnormalities during physical challenges than for differences in cognitive performance.

The contextual control of bodily arousal states provides a *unitary* functional explanation to account for observed anterior cingulate activity in a range of task situations that engender changes in peripheral autonomic activity. Embodied within this explanation is both the reactive generation of arousal responses signalling behavioural error and also a prospective role for the ACC in facilitating behavioural responses. This is achieved by optimizing bodily readiness prior to engaging in further behaviour. Observations of aboulia and motivational impairments in some patients with large cingulate lesions (Devinsky *et al.*, 1995; Cohen *et al.*, 1999) may arise from the lack of a self-initiated preparatory bodily state, in the absence of attentional or frontal executive impairments. Evidence from our previous studies has highlighted the contribution of afferent somatic and visceral information to ACC activity during contextual modulation of autonomic arousal (Critchley *et al.*, 2001*b, c*). Disruption of this second level of somatic feedback control may partly account for the increased variability in arousal responses to physical challenges (such as the cold pressor or tilt autonomic tests) that we observed in patients with anterior cingulate lesions.

Dualistic treatments of autonomic responses as mere epiphenomena in relation to neural activity engendered by cognitive task performance may be partly explained on the basis of previous methodological restrictions. Thus, many interpretations of evoked brain activity have been biased towards cognitive models. However, continuous physiological monitoring of subjects during event-related fMRI has enabled the exploration of integrative neural mechanisms facilitating behaviour that necessarily include modulation and feedback of bodily arousal states. Our observations argue for a central role of the ACC in the production and control of such behaviourally integrated patterns of autonomic activity. The data also point to the importance of accounting for bioregulatory states engaged by cognitive task manipulations in the interpretation of imaging data.

Acknowledgements

This work was supported by a Programme Grant to R.J.D. from the Wellcome Trust. H.D.C. is supported by a Wellcome Clinician Scientist Fellowship. The help and advice of K. Bleasdale-Barr, P. Cariga, M. Lowe, L. Mason, E. Featherstone, J. Stevens, J. Rees, P. Allen and W. Penny are gratefully acknowledged.

References

- An X, Bandler R, Ongur D, Price JL. Prefrontal cortical projections to longitudinal columns in the midbrain periaqueductal gray in macaque monkeys. *J Comp Neurol* 1998; 401: 455–79.
- Athwal BS, Berkley KJ, Hussain I, Brennan A, Craggs M, Sakakibara R, et al. Brain responses to changes in bladder volume and urge to void in healthy men. *Brain* 2001; 124: 369–77.
- Aziz Q, Schnitzler A, Enck P. Functional neuroimaging of visceral sensation. *J Clin Neurophysiol* 2000; 17: 604–12.
- Barris RW, Schuman HR. Bilateral anterior cingulate gyrus lesions; syndrome of the anterior cingulate gyri. *Neurology* 1953; 3: 44–52.
- Buchanan SL, Powell DA. Cingulate cortex: its role in Pavlovian conditioning. *J Comp Physiol Psychol* 1982; 96: 755–74.
- Buchel C, Bornhovd K, Quante M, Glauche V, Bromm B, Weiller C. Dissociable neural responses related to pain intensity, stimulus intensity, and stimulus awareness within the anterior cingulate cortex: a parametric single-trial laser functional magnetic resonance imaging study. *J Neurosci* 2002; 22: 970–6.
- Burgess PW, Shallice T. *The Hayling and Brixton Tests*. Bury St. Edmunds (UK): Thames Valley Test Company; 1997.
- Burns SM, Wyss JM. The involvement of the anterior cingulate cortex in blood pressure control. *Brain Res* 1985; 340: 71–7.
- Bush G, Luu P, Posner MI. Cognitive and emotional influences in anterior cingulate cortex. *Trends Cogn Sci* 2000; 4: 215–22.
- Bussey TJ, Everitt BJ, Robbins TW. Dissociable effects of cingulate and medial frontal cortex lesions on stimulus–reward learning using a novel Pavlovian autoshaping procedure for the rat. Implications for the neurobiology of emotion. *Behav Neurosci* 1997; 111: 908–19.
- Carter CS, Botvinick M, Cohen JD. The contribution of the anterior cingulate cortex to executive processes in cognition. *Rev Neurosci* 1999; 10: 49–57.
- Carter CS, Macdonald AM, Botvinick M, Ross LL, Stenger VA, Noll D, et al. Parsing executive processes: strategic vs. evaluative functions of the anterior cingulate cortex. *Proc Natl Acad Sci USA* 2000; 97: 1944–8.
- Chefer SI, Talan MI, Engel BT. Central neural correlates of learned heart rate control during exercise: central command demystified. *J Appl Physiol* 1997; 83: 1448–53.
- Cohen RA, Kaplan RF, Moser DJ, Jenkins MA, Wilkinson H. Impairments of attention after cingulotomy. *Neurology* 1999; 53: 819–24.
- Critchley HD, Corfield, DR, Chandler MP, Mathias CJ, Dolan RJ. Cerebral correlates of autonomic cardiovascular arousal: a

- functional neuroimaging investigation in humans. *J Physiol* 2000a; 523: 259–70.
- Critchley HD, Elliott R, Mathias CJ, Dolan RJ. Neural activity relating to generation and representation of galvanic skin conductance response: a functional magnetic resonance imaging study. *J Neurosci* 2000b; 20: 3033–40.
- Critchley HD, Mathias CJ, Dolan RJ. Neural activity in the human brain relating to uncertainty and arousal during anticipation. *Neuron* 2001a; 29: 537–45.
- Critchley HD, Mathias CJ, Dolan RJ. Neuroanatomical correlates of first- and second-order representation of bodily states. *Nat Neurosci* 2001b; 2: 207–12.
- Critchley HD, Melmed RN, Featherstone E, Mathias CJ, Dolan RJ. Brain activity during biofeedback relaxation: a functional neuroimaging investigation. *Brain* 2001c; 124: 1003–12.
- Devinsky O, Morrell MJ, Vogt BA. Contributions of anterior cingulate cortex to behaviour. *Brain* 1995; 118: 279–306.
- Eckberg DL. Sympathovagal balance. *Circulation* 1997; 96: 3224–32.
- Folz EL, White LE. Pain relief by frontal cingulotomy. *J Neurosurg* 1992; 19: 89–100.
- Fredrikson M, Furmark T, Olsson MT, Fischer H, Andersson J, Langstrom B. Functional neuroanatomical correlates of electrodermal activity: a positron emission tomographic study. *Psychophysiology* 1998; 35: 179–85.
- Friston KJ, Holmes AP, Price CJ, Buchel C, Worsley KJ. Multisubject fMRI studies and conjunction analyses. *Neuroimage* 1999; 10: 385–96.
- Gehring WJ, Fencsik DE. Functions of the medial frontal cortex in the processing of conflict and errors. *J Neurosci* 2001; 21: 9430–7.
- Genovese CR, Lazar NA, Nichols T. Thresholding of statistical maps in functional neuroimaging using the false discovery rate. *Neuroimage* 2002; 15: 870–8.
- Hadland KA, Rushworth MF, Gaffan D, Passingham RE. The anterior cingulate and reward-guided selection of actions. *J Neurophysiol* 2003; 89: 1161–4.
- Hoshikawa Y, Yamamoto Y. Effects of Stroop color-word conflict test on the autonomic nervous system responses. *Am J Physiol* 1997; 272: H1113–21.
- Kaada BR. Somato-motor, autonomic and electrocorticographic responses to electrical stimulation of rhinencephalic and other structures in primates, cat and dog. *Acta Physiol Scand* 1951; 24 Suppl 83: 1–285.
- Kaada BR, Pribram KH, Epstein JA. Respiratory and vascular responses in monkeys from temporal pole, insula orbital surface and cingulate gyrus. *J Neurophysiol* 1949; 12: 347–56.
- Lane RD, Reiman EM, Ahern GL, Thayer JF. Activity in medial prefrontal cortex correlates with vagal component of heart rate variability during emotion. *Brain Cogn* 2001; 47: 97–100.
- Laplante D, Degos JD, Baulac M, Gray F. Bilateral infarction of the anterior cingulate gyri and of the fornices. Report of a case. *J Neurol Sci* 1981; 51: 289–300.
- Liotti M, Brannan S, Egan G, Shade R, Madden L, Abplanalp B, et al. Brain responses associated with consciousness of breathlessness (air hunger). *Proc Natl Acad Sci USA* 2001; 98: 2035–40.
- Mathias CJ, Bannister R. Investigation of autonomic disorders. In: Mathias CJ, Bannister R, editors. *Autonomic failure: a textbook of clinical disorders of the autonomic nervous system*. 4th ed. Oxford: Oxford University Press; 1999. p. 169–95.
- McKenna P, Warrington EK. *The Graded Naming Test*. Windsor (UK): NFER-Nelson; 1980.
- Meunier M, Bachevalier J, Mishkin M. Effects of orbital frontal and anterior cingulate lesions on object and spatial memory in rhesus monkeys. *Neuropsychologia* 1997; 35: 999–1015.
- Montano N, Porta A, Malliani A. Evidence for central organization of cardiovascular rhythms. *Ann NY Acad Sci* 2001; 940: 299–306.
- Nelson HE. A modified card sorting test sensitive to frontal lobe defects. *Cortex* 1976; 12: 313–24.
- Nielsen JM, Jacobs LL. Bilateral lesions of the anterior cingulate gyri. Report of case. *Bull Los Angeles Neurol Soc* 1951; 16: 231–4.
- Ochsner KN, Kosslyn SM, Cosgrove GR, Cassem EH, Price BH, Nierenberg AA, et al. Deficits in visual cognition and attention following bilateral anterior cingulotomy. *Neuropsychologia* 2001; 39: 219–30.
- Ongur D, An X, Price JL. Prefrontal cortical projections to the hypothalamus in macaque monkeys. *J Comp Neurol* 1998; 401: 480–505.
- Osterreith PA. Le test de copie d'une figure complexe. *Arch Psychol* 1944; 30: 206–365.
- Pagani M, Lombardi F, Guzzetti S, Rimoldi O, Furlan R, Pizzinelli P, et al. Power spectral analysis of heart rate and arterial pressure variabilities as a marker of sympatho-vagal interaction in man and conscious dog. *Circ Res* 1986; 59: 178–93.
- Paus T, Koski L, Caramanos Z, Westbury C. Regional differences in the effects of task difficulty and motor output on blood flow response in the human anterior cingulate cortex: a review of 107 PET activation studies. *Neuroreport* 1998; 9: R37–47.
- Phan KL, Wager T, Taylor SF, Liberzon I. Functional neuroanatomy of emotion: a meta-analysis of emotion activation studies in PET and fMRI. *Neuroimage* 2002; 16: 331–48.
- Pool JL, Ransohoff J. Autonomic effects on stimulating the rostral portion of the cingulate gyri in man. *J Neurophysiol* 1949; 12: 385–92.
- Porrino LJ, Goldman-Rakic PS. Brainstem innervation of prefrontal and anterior cingulate cortex in the rhesus monkey revealed by retrograde transport of HRP. *J Comp Neurol* 1982; 205: 63–76.
- Rainville P. Brain mechanisms of pain affect and pain modulation. *Curr Opin Neurobiol* 2002; 12: 195–204.
- Reitan RM, Wolfson D. *The Halstead-Reitan Neuropsychological Test Battery*. Tucson (AZ): Neuropsychology Press; 1985.
- Rowe JB, Toni I, Josephs O, Frackowiak RS, Passingham RE. The prefrontal cortex: response selection or maintenance within working memory? *Science* 2000; 288: 1656–60.

- Spreen O, Strauss EA. A compendium of neuropsychological tests. 2nd ed. New York: Oxford University Press; 1998.
- Swick D, Turken AU. Dissociation between conflict detection and error monitoring in the human anterior cingulate cortex. *Proc Natl Acad Sci USA* 2002; 99: 16354–9.
- Tow PM, Whitty CWM. Personality changes after operations on the cingulate gyrus in man. *J Neurol Neurosurg Psychiatry* 1953; 16: 186–93.
- Trener MR, Crosson B, DeBoe J, Lebere, WR. Stroop Neuropsychological Screening Test. Odessa (FL): Psychological Assessment Resources; 1989.
- Turken AU, Swick D. Response selection in the human anterior cingulate cortex. *Nat Neurosci* 1999; 2: 920–4.
- Turner DL. Cardiovascular and respiratory control mechanisms during exercise: an integrated view. *J Exp Biol* 1991; 160: 309–40.
- van Veen V, Cohen JD, Botvinick MM, Stenger VA, Carter CS. Anterior cingulate cortex, conflict monitoring, and levels of processing. *Neuroimage* 2001; 14: 1302–8.
- Vilensky JA, van Hoesen GW. Corticopontine projections from the cingulate cortex in the rhesus monkey. *Brain Res* 1981; 205: 391–5.
- Vogt BA, Finch DM, Olson CR. Functional heterogeneity in cingulate cortex: the anterior executive and posterior evaluative regions. *Cereb Cortex* 1992; 2: 435–43.
- Walton ME, Bannerman DM, Rushworth MF. The role of rat medial frontal cortex in effort-based decision making. *J Neurosci* 2002; 22: 10996–1003.
- Ward AA. The cingulate gyrus: area 24. *J Neurophysiol* 1948; 11: 13–34.
- Warrington EK. The Recognition Memory Test. Windsor (UK): NFER-Nelson; 1984.
- Warrington EK. The Camden Memory Tests. Hove (UK): Psychology Press; 1996.
- Warrington EK, James M. The Visual Object and Space Perception Battery. Bury St. Edmunds (UK): Thames Valley Test Company; 1991.
- Wechsler DA. Wechsler Adult Intelligence Scale: Manual. New York: Psychological Corporation; 1955.
- Wechsler DA. Wechsler Adult Intelligence Scale—Revised: Manual. New York: Psychological Corporation; 1981.
- Wilson BA, Alderman N, Burgess P, Emslie H. Behavioural Assessment of the Dysexecutive Syndrome (BADS). Bury St. Edmunds (UK): Thames Valley Test Company; 1996.

Received February 3, 2003. Revised March 19, 2003.

Accepted April 28, 2003